

CASE REPORT

UTERUS DIDELPHYS WITH OBSTRUCTED HEMIVAGINA, HEMATOCOLPOS, AND HEMATOMETRA

Shakila Yasmin¹, Sidrah Batool²

¹Professor, Department of Gynecology and Obstetrics, Bahawal Victoria Hospital, Bahawalpur

²Senior Registrar, Department of Gynecology and Obstetrics, Bahawal Victoria Hospital, Bahawalpur

ABSTRACT

Uterus didelphys presenting with the obstructed hemi-vagina, hematocolpos, and hematometra is an infrequent entity and is usually diagnosed late as patients often have normal menstrual cycles. If it is associated with ipsilateral renal agenesis, the condition is called Herlyn-Werner-Wunderlich syndrome (HWW). Patients with this condition present with progressive pelvic pain after menarche, urinary retention, and palpable mass. It is usually due to the presence of hematocolpos and hematometra. Condition is diagnosed on the basis of genitourinary symptoms, local examination, and radiological findings.

A 20-year-old married woman was admitted through the outpatient department of gynae unit II, Bahawal Victoria Hospital, Bahawalpur with the complaint of painful menstruation since menarche for 5 years. She always had to use analgesics for dysmenorrhea. She visited tertiary care for the first time on 28 May 2023. On ultrasonography, the patient was suspected to have a double uterus with hematocolpos and hematometra. The patient was put on the list for Examination Under Anesthesia (EUA) where the vaginal septum was excised, hematocolpos and hematometra drained, and hemostasis secured. Patient discharged on 3rd post-op day.

Keywords: *Uterus didelphys, obstructed hemivagina, hematocolpus, hematometra, pelvic pain*

INTRODUCTION:

The uterus is derived from two paramesonephric ducts that extend caudally and fuse in the midline to form the uterus and cervix while the upper portion remains patent and develops into fallopian tubes. The upper one-fourth of the vagina is developed from the Mullerian duct while the lower fifth is developed from the urogenital sinus¹. Uterus didelphys is a symmetrical anomaly that occurs due to the failure of fusion of mesonephric ducts. Malformations of the female genital tract occur due to disturbance of embryological development of Mullerian ducts caused by various environmental, genetic, and

teratogenic factors. The mean prevalence of female genital tract malformation is up to 7%². Uterus didelphys constitutes approximately 10% and obstructed hemivagina constitutes approximately 12%³. Various classification systems for genital tract anomalies have been published⁴. Clinical symptoms are primary amenorrhea, cyclical pain in the pelvic area, lower abdominal mass, infertility, urinary retention, and endometriosis, or may be asymptomatic. Accurate diagnosis should be made at the earliest to treat severe dysmenorrhea and future sub-fertility. The appropriate treatment includes the excision of the vaginal septum along with the drainage of hematocolpos and hematometra.

CASE PRESENTATION

A 20-year-old lady, married for six months R/O Ahmadpur admitted to Gynae Unit II, Bahawal

Correspondence: Sidrah Batool
Bahawal Victoria Hospital, Bahawalpur
E-mail: sidrahbatool14@gmail.com

Victoria Hospital, Bahawalpur through OPD on 28-5-2023 with the complaint of painful menstruation for the last 5 years. The pain started one day before the onset of menses, moderate in intensity and dull in character, associated with nausea and vomiting, relieved by menstruation and taking analgesics, aggravated by performing household activities, but no urinary and bowel symptoms. Her menstrual cycle was regular with the average flow, and she used to bleed for 4 days after every 28 days and used to soak 1-2 homemade sanitary pads that were mildly soaked there was no history of intermenstrual or postcoital bleeding or dyspareunia. She menarched at the age of 15 years, the couple never practiced any method of contraception, and a pap smear was never taken. She is nulliparous. Her medical, surgical, drug, and hospitalization history was not significant. She was admitted to the ward, and her EUA was

planned for further management. On ultrasonography, uterus didelphys bicollis with left hemivagina ending blindly and hematocolpos was suspected. On examination under anesthesia, uterus didelphys was confirmed, the right-sided uterine cavity was 9cm with a nulliparous cervix while the left-sided cervix could not be visualized properly, there was a large bulge approximately 7x7 cm occupying the left side of the vagina that was due to the transverse vaginal septum. The septum was excised, hematocolpos (approximately 100 ml) drained and marsupialization of blind hemivagina was done to prevent a recurrence. Prophylactic intravenous antibiotics and analgesics were advised, and the patient was discharged on 2nd post-op day.

Figure: 1

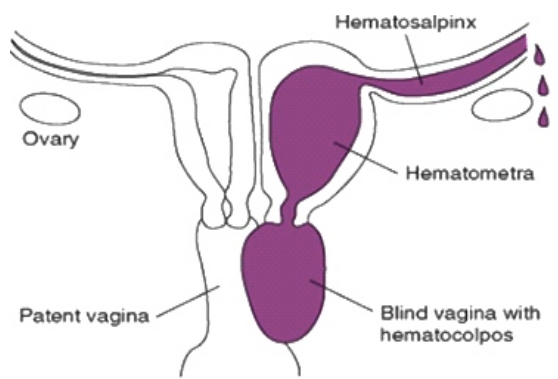
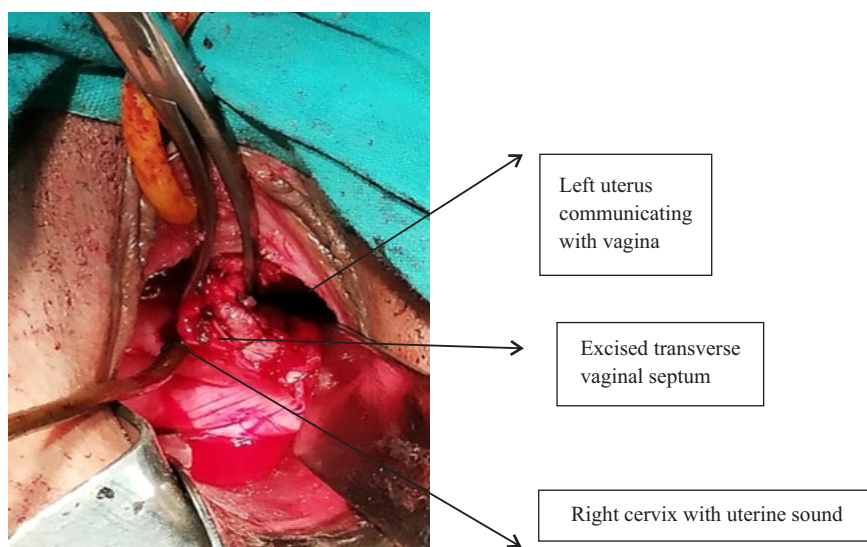


Figure: 2



DISCUSSION:

There should be a clear diagnostic and therapeutic strategy for patients presenting with c/o dysmenorrhea and menstrual irregularities in whom we suspect congenital malformation of the genital tract so that unnecessary surgical intervention should be avoided. A basic pelvic USG should be done, but MRI is more accurate to completely diagnose such a condition,⁵ and laparoscopy might be helpful when imaging is not clear. Laparoscopic surgery has additional benefits for the treatment of concurrent problems like endometriosis. Abnormal renal development on the side of the obstructed vagina associated with a double uterus and a double cervix indicates a fetal arrest in the eighth week of pregnancy that simultaneously affects the Mullerian duct and metanephric ducts.⁶ Such complex cases are treated with operative laparoscopy.⁷

Such genitourinary congenital anomalies are detected in-utero by a detailed anomaly scan in the second trimester by a consultant radiologist, which may include a multicystic kidney, absent kidney, or cystic mass due to muco/hydrocolpos behind the urinary bladder.⁸ In asymptomatic infants with absent kidneys and small uteruses, it is almost impossible to diagnose uterine anomalies so we should follow such infants till the end of puberty when they might have symptoms.⁹ Hysteroscopic resection of vaginal septum under trans-abdominal ultrasound guidance in uterus didelphys with obstructed hemivagina is an excellent alternative to conventional treatment. In such cases, resectoscopic excision under ultrasonographic control of unilateral imperforate hemi-vagina is performed. It is simpler, safer, and prevents hymen disruption as compared to conventional excision of the septum with the use of scissors or a scalpel which includes hymen disruption and wide exposure to the vagina.^{10, 11}

CONCLUSION:

The congenital urogenital anomalies in females are

very diverse. Some mullerian anomalies are easily diagnosed but others have very unusual presentations that make diagnosis and management difficult. A good knowledge of basic embryology is important for understanding the pathogenesis and clinical features of these anomalies. All gynecologists should be aware of these conditions and their possible clinical presentation so that early diagnosis and prompt treatment should be done.

REFERENCES:

1. Passos IMPE, Britto RL. Diagnosis and treatment of müllerian malformations. *Taiwan J Obstet Gynecol.* 2020 Mar;59(2):183-188.
2. Peixoto Silva A, Souza Neves S, Tannure Saraiva PH, Bicalho Bretas TA. Hemihysterectomy in a patient with uterus didelphys, vaginal septum and ipsilateral renal agenesis: A case report and literature review. *Int J Gynaecol Obstet.* 2024 Jun;165(3):969-974.
3. Choridah L, Pangastuti N. Obstructed hemivagina and ipsilateral renal anomaly syndrome in an association with endometriosis: Role of Magnetic Resonance Imaging in diagnosis. *Med J Malaysia.* 2024 Aug;79(Suppl 4):83-86.
4. Huseyin K, Lale TS, Burak Y, Tolga K, Pinar K, Kerem SD. A case of obstructed hemivagina and ipsilateral renal anomaly syndrome complicated with pyometra: tips and tricks for laparoscopic hemihysterectomy. *Fertil Steril.* 2019 Jul;112(1):177-179.
5. Moufawad G, Giannini A, D'Oria O, Laganà AS, Chiantera V, Khazzaka A, et al. Obstructed Hemivagina and Ipsilateral Renal Anomaly Syndrome: A Systematic Review about Diagnosis and Surgical Management. *Gynecol Minim Invasive Ther.* 2023 Aug 10;12(3):123-129.
6. Moufawad G, Ayed A, Sleiman Z. Reconsidering the best minimally invasive approach for patients with herlyn-werner-wunderlich syndrome: Should we push the frontiers for a better

outcome? *Front Surg.* 2023 Apr 11;10:1158753.

7. Nishu DS, Uddin MM, Akter K, Akter S, Sarmin M, Begum S. Herlyn-Werner-Wunderlich syndrome presenting with dysmenorrhea: a case report. *J Med Case Rep.* 2019 Oct 31;13(1):323.

8. Borges AL, Sanha N, Pereira H, Martins A, Costa C. Herlyn-Werner-Wunderlich syndrome also known as obstructed hemivagina and ipsilateral renal anomaly: A case report and a comprehensive review of literature. *Radiol Case Rep.* 2023 Jun 6;18(8):2771-2784.

9. Hayat AM, Yousaf KR, Chaudhary S, Amjad S. The Herlyn-Werner-Wunderlich (HWW) syndrome

- A case report with radiological review. *Radiol Case Rep.* 2022 Mar 2;17(5):1435-1439.

10. Liu M, Zhang L, Xia Y, Huang X, Ye T, Zhang Y, Qi Z, Wang L, Lai X, Dai Q, Jiang Y. New Consideration of Herlyn-Werner-Wunderlich Syndrome Diagnosed by Ultrasound. *J Ultrasound Med.* 2021 Sep;40(9):1893-1900.

11. Candiani M, Ruffolo AF, Fedele F, Salvatore S, Parazzini F. Conservative Treatment of Didelphic Uterus with Obstructed Hemivagina and Ipsilateral Renal Agenesis. *J Minim Invasive Gynecol.* 2022 Aug;29(8):929.